

Case Report

Trigger point injections as a potential risk for psoas abscess

Naoko Kamiya, MD^{1,2}, Masami Matsumura, MD, PhD²¹ Department of General Medicine, Shinshiro Municipal Hospital, Shinshiro-shi, Aichi, Japan.² Division of General Internal Medicine, Jichi Medical University Hospital, Shimotsuke-shi, Tochigi, Japan.**Abstract**

A 92-year-old man taking 5 mg per day of oral prednisolone presented with exacerbation of low back pain. He had been received frequent trigger point injections (TPIs) for lumbar canal stenosis. Physical examination revealed an area of tenderness on the right lower back which was consistent with the location of the TPIs and the contrast computed tomography (CT) scan showed an intramuscular abscess in the right iliopsoas. He was transferred to the tertiary medical institution, and the culture obtained by CT guided percutaneous abscess drainage yielded *Streptococcus pyogenes*, which is a part of the skin flora and pathogenic bacteria. Psoas abscess might have been caused by frequent TPIs in this case. This case report illustrates TPI is a potential risk factor for muscle abscess, especially in aged and compromised patients.

(Keywords: aged patient, compromised patient, psoas abscess, trigger point injection)

Introduction

Trigger point injection (TPI) is a common technique for the treatment of painful muscle areas. TPI is generally considered an easy, safe, and effective procedure and is widely used by physicians and orthopedic surgeons in primary care settings to relieve chronic pain which is unresponsive to medical treatments. However, some cases with complications following TPIs, such as hematoma, epidural abscess, and pneumothorax are reported¹⁻³.

Here, we report a case of psoas abscess following TPIs against a background of high age and compromised patient. This case report aims to draw attention to the potential risk factors of muscle abscess following TPIs.

Case report

A 92-year-old man presented with exacerbation of low back pain that had occurred two weeks before our initial examination. He had been taking 5 mg per day of oral prednisolone for polymyalgia rheumatica for over ten years and received frequent TPIs for lumbar canal stenosis by an orthopedic surgeon. Physical examination revealed a fever of over 37.5 degrees Celsius and an area of tenderness on the right lower back which was consistent with the location of the TPIs. Laboratory tests showed a white cell count of 14,200/ μ L and C-reactive protein 22.09 mg/dL. Urinalysis including sediments disclosed no abnormalities.

The contrast computed tomography (CT) scan revealed an intramuscular multiloculated abscess in the right iliopsoas (Figure 1). The blood culture was sterile. He was transferred to the tertiary medical institution for further evaluation and treatment. Empiric antimicrobial administration was started, and CT guided percutaneous catheter drainage was performed. The culture of the specimen from the lesion yielded *Streptococcus pyogenes*. Sulbactam/ampicillin was administered intravenously for ten weeks, followed by oral levofloxacin administration for four weeks based on the susceptibility testing with improvement.

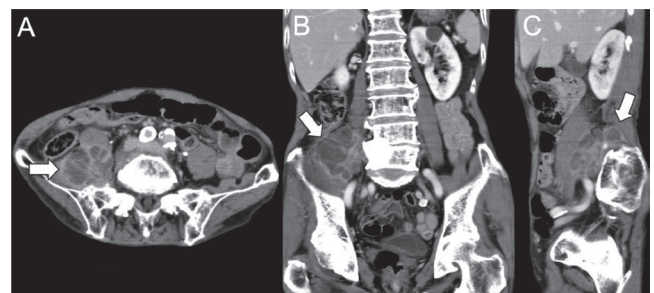


Figure 1. Horizontal (A), coronal (B), and sagittal (C) CT images show intramuscular multiloculated abscess in the right iliopsoas.

Discussion

We report a case of psoas abscess which was consistent with the location of frequent TPIs for lumbar canal stenosis. The patient was an oldest-old man taking prednisolone without obvious organic etiologies including trauma, hematoma, and instrumentation in the body. In this case, psoas abscess might have been caused by frequent TPIs against a background of high age and compromised host. TPIs could occur muscle abscess despite performing the procedure with careful aseptic techniques.

Psoas abscess is a relatively rare infection that carries a risk of disability and mortality, that is classified as primary or secondary according to the presence or absence of underlying disease. Primary psoas abscess occurs as a result of hematogenous seeding of the pathogenic microorganism from an occult source. Secondary psoas abscess occurs as a result of the direct spread of infection to the psoas muscle. Crohn's disease is the most frequent cause of secondary psoas abscess, and other causes are appendicitis, colonic inflammation or neoplasm, genitourinary disease, and vertebral osteomyelitis^{4,5}. We performed a CT scan in this case, which clarified not only the definitive diagnosis but also the extension of the abscess. CT provides high sensitivity for psoas abscess and can delineate the pathologic process. On the other hand, magnetic resonance imaging is often superior in differentiating between abscess, hematoma, and tumor⁶. In this case, organic etiologies were not detected.

The major causative organism is *Staphylococcus aureus* in primary abscess⁵. Mixed infection with enteric organisms is frequent in secondary psoas abscess⁵. *S. aureus* is a major cause of spinal epidural abscess after the technique of puncture through the skin⁷. *S. pyogenes* detected in this case is also known to be a part of the skin flora and a pathogenic bacteria causing various diseases such as upper respiratory inflammation, skin infection, otitis media, pneumonia, and arthritis according to entry site and tissue.

TPI is a technique for the treatment of painful areas of muscle, that is regarded to be relatively safe. Many previous studies about the effectiveness of TPI reported very few adverse effects, and the most common complications following TPI were reported to be mild adverse effects such as bruising, hemorrhage, and pain^{8,9}. As far as we know, only two case reports described abscesses associated with TPI, which are epidural abscess and retrosternal abscess^{2,10}.

In conclusion, TPI is relatively safe in most cases. However, serious complications can result from this procedure. We should consider TPI as a potential risk factor for muscle abscess, especially in aged and compromised patients.

Declaration of interest

The authors declare no conflicts of interest in this article.

Acknowledgments

We thank John Gelblum for his critical reading of the manuscript.

References

1. Kim SG, Shim KS, Lee DW, et al. Intramuscular hematoma with motor weakness after trigger point injection: A case report. *Medicine*. 2017; 96(39): e8135.
2. Elias M. Cervical epidural abscess following trigger point injection. *Journal of pain and symptom management*. 1994; 9(2): 71-72.
3. Ahiskalioglu EO, Alici HA, Dostbil A, Celik M, Ahiskalioglu A, Aksoy M. Pneumothorax after trigger point injection: A case report and review of literature. *Journal of back and musculoskeletal rehabilitation*. 2016; 29(4): 895-897.
4. Mallick IH, Thoufeeq MH, Rajendran TP. Iliopsoas abscesses. *Postgraduate medical journal*. 2004; 80(946): 459-462.
5. Ricci MA, Rose FB, Meyer KK. Pyogenic psoas abscess: worldwide variations in etiology. *World journal of surgery*. 1986; 10(5): 834-843.
6. Negus S, Sidhu PS. MRI of retroperitoneal collections: a comparison with CT. *The British journal of radiology*. 2000; 73(872): 907-912.
7. Reihnsaus E, Waldbaur H, Seeling W. Spinal epidural abscess: a meta-analysis of 915 patients. *Neurosurgical review*. 2000; 23(4): 175-204; discussion 205.
8. Scott NA, Guo B, Barton PM, Gerwin RD. Trigger point injections for chronic non-malignant musculoskeletal pain: a systematic review. *Pain medicine (Malden, Mass)*. 2009; 10(1): 54-69.
9. Kocak AO, Ahiskalioglu A, Sengun E, Gur STA, Akbas I. Comparison of intravenous NSAIDs and trigger point injection for low back pain in ED: A prospective randomized study. *The American journal of emergency medicine*. 2019; 37(10): 1927-1931.
10. Usman F, Bajwa A, Shujaat A, Cury J. Retrosternal abscess after trigger point injections in a pregnant woman: a case report. *Journal of medical case reports*. 2011; 5: 403.

トリガーポイント注射は腸腰筋膿瘍の要因となりうる

神谷 尚子^{1,2}, 松村 正巳²

1) 新城市民病院 総合診療科 〒441-1387 愛知県新城市字北畑32-1

2) 自治医科大学附属病院 総合診療内科 〒329-0498 栃木県下野市薬師寺3311-1

要 約

症例は92歳、男性。5 mg/日のプレドニゾロンを10年以上内服しており、増悪する腰痛を主訴に来院した。腰部脊柱管狭窄症の既往があり、腰痛に対して、頻回のトリガーポイント注射を受けていた。身体所見では、トリガーポイント注射と一致する右下背部に圧痛を認めた。造影CT検査では、右腸腰筋内に膿瘍を認めたが、腸腰筋膿瘍の原因となりうる器質的疾患は認めなかった。診断後、患者はさらなる処置と治療のため、高次医療機関に転院となり、CTガイド下膿瘍ドレナージによって採取した検体から、A群β溶血性連鎖球菌が検出された。A群β溶血性連鎖球菌は皮膚の常在細菌の1つであるが、様々な疾患の原因になりうる。本症例は、頻回なトリガーポイント注射によって生じたと思われる腸腰筋膿瘍であり、特に免疫抑制状態にある高齢者においては、トリガーポイント注射が筋肉内膿瘍の原因となりうることを考慮すべきである。

(キーワード: 高齢者, 易感染性宿主, 腸腰筋膿瘍, トリガーポイント注射)